

THE EFFECTS OF "HOI XUAN HOAN" CAPSULES ON SPERM COLLECTION EFFICIENCY AND MORPHOLOGICAL SPERM STRUCTURE OBTAINED BY MICRO IN NONOBSTRUCTIVE AZOOSPERMIA PATIENTS

Quach Thi Yen^{1,2}, Quan Hoang Lam¹, Trinh Quoc Thanh¹
Doan Minh Thuy², Vu Thi Hao³

SUMMARY

Objectives: To evaluate the efficiency of sperm collection and describe the characteristics of sperm structure obtained from microdissection testicular sperm extraction (micro tese) in non-obstructive azoospermia patients (NOA) after using the capsule "Hoi xuan hoan". **Subjects and methods:** 88 NOA patients were divided into 2 groups: Group 1: 41 patients were treated with capsule "Hoi xuan hoan" for 3 months and group 2: 47 patients had no treatment. These patients were taken micro at the Military Clinical Embryo Institute, Vietnam Military Medical University from 5/2017 to 12/2019. **Results:** The rate of sperm collection by micro method was 39.77%, of which group 1 was 46.34% and group 2 was 34.04%; The sperm collection median density in group 1 was 2 million/mL higher than group 2 with 0.5 million/mL significantly ($p < 0.05$). The rate of alive sperm, normal morphological sperm and mobile sperm ratio in group 1 was higher than that in group 2 ($p > 0.05$). **Conclusions:** "Hoi xuan hoan" capsules helped to improve the process of spermatogenesis inside the testes, thereby increasing the density and the chance of obtaining sperm by micro in NOA patients.

* **Keywords:** Microsurgical testicular sperm; Micro tese; Non-obstructive azoospermia.

INTRODUCTION

Azoospermia is a condition in which there is no sperm in semen. This is the most severe cause of infertility in men, accounting for 5% of infertile couples [1]. Infertility is classified as obstructive and non-obstructive one. In the non-obstructive

group, the testes reduces sperm production severely or there is no sperm at all. Traditional medicine has been used to treat male infertility for a long time has been shown to play a role in improving process of spermatogenesis in experiments and in patients with impaired spermatogenesis [4].

¹Military Clinical Embryo Institute, **Vietnam Military Medical University**

²Department of Embryo Histology, Vietnam University of Traditional Medicine

³Department of Foreign Language, Thai Nguyen University of Medicine and Pharmacy

Corresponding author: Quach Thi Yen (quachthiyen888@gmail.com)

Date received: 28/7/2020

Date accepted: 28/8/2020

In 1992, the introduction of intracytoplasmic sperm injection technique opened up the opportunity of being fatherhood for azoospermia men. Wishing to find a remedy to stimulate spermatogenesis inside the testes, increase the chances of sperm collection in the infertile men, helping these patients have their own children, we conducted the project with the goal: *To evaluate the efficiency of sperm collection and describe the morphological structure of sperm collected from the testes by micro testis method after using "Hoi xuan hoan" capsules.*

SUBJECTS AND METHODS

1. Subjects

88 NOA patients were given testis microphonies at the Military Clinical Embryo Institute, Vietnam Military Medical University and Morphology Department 69, Headquarter of Ho Chi Minh Mausoleum from 5/2017 to 12/2019.

* *Selection criteria:* Patient without sperm in their semen were selected according to WHO's criteria 2010, excluding retrograde ejaculation [5]. NOA patients were randomly divided into 2 groups: Group 1 consisted of 41 patients treated with "Hoi xuan hoan" capsules, taking 10 capsules/day, each 3 doses for 3 consecutive months before taking micro; group 2 consisted of 47 patients who were not treated and immediately performed microphonies.

* *Exclusion criteria:* Cases of acute diseases, social diseases, endocrine

diseases, taking drugs and chemicals affecting processes of spermatogenesis.

2. Materials

The "Hoi xuan hoan" capsule is registered under the name "Khang bao tu", No. 1497/2015/ATTP-XNCB.

Ingredients of 01 Hoi xuan hoan 500 mg capsule: *Radix Rehmanniae glutinosae praeparata* 2.4g, *Fructus Corni* 1.2g, *Rhizoma Dioscorea persimilis* 1.6g, *Radix Glycyrrhizae* 1.2g, *Cortex Cinnamomi* 1.2g, *Radix Aconiti lateralis praeparata* 1.2g, *Cortex Eucommiae* 1.6g, *Fructus Lycii* 1.6g, *Colla Cornus Cervi* 1.0g and other excipients.

Dosage form: Hard capsule, each "Hoi xuan hoan" capsule contains 500 mg high dried medicinal herbs. All the materials used in the "Hoi xuan hoan" capsules have met the quality of Vietnamese Pharmacopoeia standards III; high dried medicinal herbs "Hoi xuan hoan" has met manufacturer's standard; Capsule Khang Bao Tu has been confirmed to meet food safety regulations.

3. Methods

* *Study design:* Controlled clinical trial.

Characteristics of micro sperm is evaluated by WHO standards (2010). Due to the fact that many samples have low sperm rates, we counted 100 sperm samples and evaluated the criteria according to WHO (2010) [5]. For the sperm morphology alone, we evaluated 20 samples on Papalicolaou stain.

RESULTS

1. Some characteristics of the research subjects

Table 1: Clinical and subclinical characteristics.

Clinical and subclinical characteristics	Sum ($\bar{X} \pm SD$) (n) min - max Median, 95%CI	Group 1 ($\bar{X} \pm SD$) (n) min - max Median, 95%CI	Group 2 ($\bar{X} \pm SD$) (n) min - max Median, 95%CI	p₁₂
Age (year)	31.65 ± 4.39 (88) 21 - 45 32 (30.72 - 32.58)	31.83 ± 4.84 (41) 21 - 45 32 (30.30 - 33.36)	31.49 ± 3.99 (47) 24 - 39 32 (30.32 - 32.66)	0.96
BMI (kg/h ²)	22.64 ± 2.49 (41) 17.9 - 28.8 22.49 (22.11 - 23.16)	22.69 ± 2.66 (41) 18.4 - 28.8 22.15 (21.85 - 23.53)	22.59 ± 2.37 (47) 17.9 - 28.0 22.49 (21.89 - 23.28)	0.92
Infertility time (year)	4.29 ± 2.81 (41) 1 - 14 4 (3.69 - 4.89)	4.51 ± 3.09 (41) 1 - 14 4 (3.54 - 5.49)	4.10 ± 2.57 (47) 1 - 13 3 (3.34 - 4.85)	0.69
Right testicular volume (mL)	6.54 ± 3.15 (41) 1 - 25 6 (5.86 - 7.21)	6.54 ± 2.17 (41) 3 - 12 6 (5.85 - 7.22)	6.53 ± 3.85 (45) 1 - 25 6 (5.38 - 7.69)	0.67
Left testicular volume (mL)	6.54 ± 2.92 (38) 1 - 20 6 (5.90 - 7.17)	6.37 ± 2.16 (38) 2 - 12 6 (5.66 - 7.08)	6.67 ± 3.45 (46) 1 - 20 6 (5.65 - 7.70)	0.84
FSH (mIU/mL)	19.70 ± 12.32 1.36 - 68.56 18.73 (17.09 - 22.31)	18.44 ± 11.24 1.36 - 47.06 17.21 (14.89 - 21.99)	20.80 ± 13.22 2.18 - 68.56 20.85 (16.92 - 24.68)	0.40
LH (mIU/mL)	9.72 ± 6.27 1.14 - 27.35 8.31 (8.39 - 11.05)	8.64 ± 5.43 1.43 - 26.13 7.38(6.92 - 10.35)	10.66 ± 6.84 1.14 - 27.35 8.85 (8.65 - 12.67)	0.17
Testosterone (ng/mL)	4.09 ± 2.25 1.12 - 13.96 3.44 (3.61 - 4.56)	4.00 ± 2.52 1.12 - 13.96 3.45 (3.20 - 4.79)	4.17 ± 2.01 1.17 - 10.13 3.43 (3.58 - 4.76)	0.39

2. Percentage of sperm collection by micro tese method

Among 88 NOA patients, there were 35 cases with sperm collection (39.77%); of which group 1 had 19 cases (46.34%) and group 2 had 16 cases (34.04%). The difference is not statistically significant (p > 0.05).

3. Characteristics of microcrystalline obtained from the testes after using the capsule "Hoi xuan hoan"

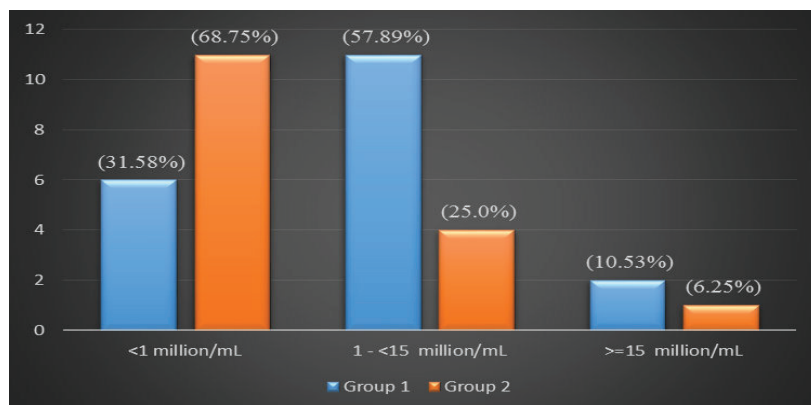


Figure 1: Density distribution of sperm obtained from the testes.

In group 1, the concentration density was mainly from 1 to < 15 million/mL (57.89%), while in group 2, the concentration was mainly below 1 million/mL (68.75%). Therefore, the difference is not statistically significant ($p > 0.05$).

The median sperm collection density in group 1 was 2 million/mL (95%CI: 0.9 - 8.0), the lowest was 0.5 million/mL and the highest was 30 million/mL, which was higher than that of group 2 was 0.5 million/mL (95%CI: -0.43 - 5.29). The difference was statistically significant ($p < 0.01$).

Table 2: The percentage of alive spermatozoa and normal morphology and sperm motility obtained from the testes.

Sperm collection ratio (%)		$\bar{x} \pm SD$	Min - max	Median	95%CI	p
Alive sperm	Group 1	35.11 ± 21.27	10 - 80	31	24.86 - 45.35	0.25
	Group 2	28.13 ± 24.39	0 - 68	17.5	15.13 - 41.12	
Normal morphology	Group 1	2.37 ± 2.57	0 - 5	0	1.13 - 3.6	0.08
	Group 2	0.94 ± 2.02	0 - 5	0	-0.14 - 2.01	
Forward motility	Group 1	5.89 ± 8.64	0 - 25	0	1.73 - 10.06	0.20
	Group 2	3.44 ± 7.69	0 - 25	0	-0.66 - 7.53	
Locally motile	Group 1	12.74 ± 10.23	0 - 35	10	7.81 - 17.67	0.23
	Group 2	8.88 ± 10.63	0 - 31	2,5	3.21 - 14.54	
Immotility	Group 1	81.89 ± 16.35	44 - 100	85	74.01 - 89.78	0.15
	Group 2	87.69 ± 16.70	54 - 100	97.5	78.79 - 96.59	

There was no difference in median rates of normal, alive and motile in the two research groups ($p > 0.05$), although the ratio of alive, normal morphology and mobile sperm tended to be higher in group 1.

Table 3: The ratio of abnormally spaped sperm obtained from the testes.

Abnormal human sperm morphology (n, %)	Head defects	Neck and midpiece defects	Tail defects	Excess residual cytoplasm	Mixed abnormality
Group 1 (n = 380)	115 (31.00)	50 (13.48)	53 (14.29)	10 (2.70)	143 (38.54)
Group 2 (n = 320)	103 (32.49)	50 (15.77)	46 (14.51)	6 (1.89)	112 (35.33)
p	> 0.05				

There was no difference in ratio of abnormal morphology in two research groups (p > 0.05).

Table 4: Teratozoospermia Index (TZI), Spermdeformity Index (SDI) in sperms obtained.

Index		Group 1 n (%)	Group 2 n (%)	p
TZI	≥ 1.72	14 (73.68)	10 (62.50)	0.51
	< 1.72	5 (26.32)	6 (37.50)	
SDI	≥ 1.62	17 (89.47)	10 (62.50)	0.17
	< 1.62	2 (10.53)	6 (37.50)	

4. Characteristics of micro sperm obtained from testes after using “Hoi xuan hoan” capsules

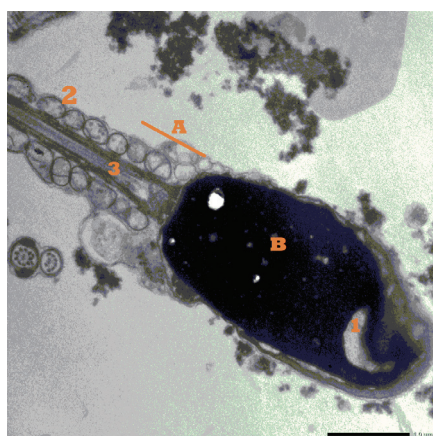


Figure 2: Superstructure of sperm from the testes of NOA patients; Code 2574 (TEM, x13.250). A. Neck; B. Chromatin; 1. Low electronic density defect; 2. Mitochondria; 4. Axis section.

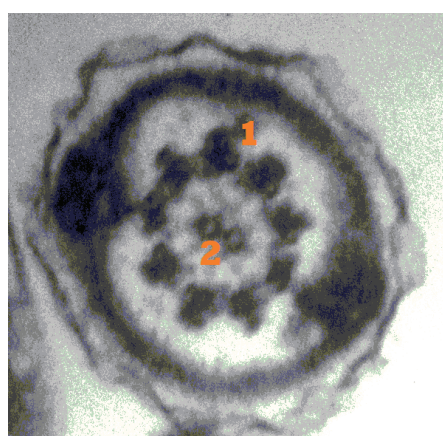


Figure 3: Superstructure spermatozoa segment (cross section) from testicle of NOA patient, code 2633 (TEM, x13.500); 1. The pair of supernatant tubes on the periphery; 2. Two pairs of central micro tubes.

Out of 09 testicular tissue samples sent as superstructures, sperm was found in 02 samples. Most of the samples were abnormal as head defects, even discontinuous head membrane of the cell, abnormal shapes of the terminal pockets. In the nucleus of some cells, chromatin densities are heterogeneous, there are defect areas represented by low electron density areas. The cytoplasm is thick, the mitochondria in the tail lose the folds (figures 2 and 3).

DISCUSSIONS

Among 88 NOA patients who received micro tese, there were 35 sperm obtained cases (39.77%), of which 19 cases in group 1 (46.34%) and 16 cases in group 2 (34.04%). There was no difference ($p > 0.05$). Ishikawa (2012) reviewed and compared the effectivity of sperm collection by micro tese method he showed that the sperm collection rate ranged from 32 - 63% [6]. Deruyver Y et al (2014) reviewed from 7 studies from 1999 to 2011 showed that the sperm collection by micro tese was 42.9 - 63% [7]. These results were similar to ours.

Regarding sperm density: Median sperm concentration in group 1 had better results than group 2 ($p < 0.05$). This showed that patients treated with "Hoi xuan hoan" capsules had better sperm density than the untreated group. According to research by Doan Minh Thuy (2010), "Hoi xuan hoan" capsules had been shown to have stimulating effect on spermatogenesis in experiment. Capsules "Hoi xuan hoan" increased sperm cell proliferation, the number of sperm in the lumen of the

spermatogenesis compared to the control group. Especially in sperm deficient patients, the "Hoi xuan hoan" capsule significantly increases the number of count sperm, increases the rate of alive sperm and normal-shaped sperm ($p < 0.05$). "Hoi xuan hoan" had a good effect on stimulating sperm production because it reduced FSH and LH levels in elevated physiological levels patients. The "Hoi xuan hoan" capsule is original from the "Chinese Organic regulation of spices". Now, both in China and in Vietnam, clinicians still use the article "Chinese Organic regulation of spices" to treat kidney failure and *Colla Cornus Cervi* is used to strengthen physical health. The ingredients *Radix Rehmanniae glutinosa praeparata*, *Rhizome dioscoreae persimilis*, *Fructus Corni*, *Fructus Lycii*, *Colla Cornus Cervi*... contain amino acids, fats, sugars, vitamins which are essential elements for the proliferation of fine epithelial epithelium and improves spermatogenesis. Microelements such as Zn, Mg, Cu as well as vitamins C and E are classified as antioxidant. In the *Fructus Lycii* contains trace elements (Ca, P, Fe, Zn), it has the effect of promoting the activity of enzymes to increase protein synthesis, especially zinc has the effect of increasing the quantity and quality of sperm [6]. Some ingredients in "Chinese Organic regulation of spices" are also studied by other authors found out that the traditional ingredients have had good effects on the process of spermatogenesis in experiments and patients with sperm production efficient. Wang Jinju (2014) studied the effect of capsules in combination with levocarnitine for 3 months in 192 patients with sperm disability showed that: After treatment

density, mobility, survival sperm rate all increased when used the capsule alone and in combination therapy, but the efficacy was even better when using the combination of the two above methods ($p < 0.05$) [8]. Zhu Zhichao (2015) studied 76 patients with oligospermia who took Wuzi Yanzong Wan (included materials: *fructus lycii*, *semen cuscutae*, *fructus rubi*, *fructus shisandrae*; *semen plantaginis*) and taking combination of Wuzi Yanzong Wan and Yougui Wan (*radix rhemaniae glutinosae praeparata*, *radix aconite lateralis praeparata*, *cortex cinnamomi*, *radix dioscoreae*, *cornaceae*, *semen cuscutae*, *colla cornus cervi*, *fructus lycii*, *radix angelicae*, *cortex eucommiae*) (each group of 38 patients), the results showed that: Density sperm, rate of sperm with forward progression and the survival sperm was significantly higher in the combined treatment group ($p < 0.05$) [9].

The rate of alive sperm and mobile sperm: Alive sperm and mobile sperm in group 1 tended to be higher than group 2, but the difference was not statistically significant ($p > 0.05$). Our results were lower than Prins S's finding (1999) with the survival rate of sperm being $55 \pm 7\%$ [10].

Sperm morphology: There was no difference in normal and abnormal morphology in the two research groups ($p > 0.05$). Among the abnormalities in group 1, the combination of abnormalities accounted for the highest proportion (38.54%), followed by the head abnormalities (31.00%), the remaining abnormal cytoplasmic abnormalities were 2.70%. Thus, the treatment with capsules "Hoi xuan hoan" in 3 months has not yet changed the mobility ability of sperm,

normal shape and survival sperm rate. Longer treatment time with larger sample size are needed to assess the effectiveness of the remedy.

Diversity and TZI index and SDI index are very important in predicting the success of assisted reproductive technologies. According to WHO 2010, the TZI and SDI are significant when the TZI index is 1.72 and the SDI index is 1.62. If the TZI index is ≥ 1.72 , the success rate of In Vitro Fertilization (IVF) technique is low. If the SDI index is ≥ 1.62 but the IVF technique is used, it will fail [5]. For that reason, TZI and SDI are essential indicators when analyzing sperm morphology, especially for samples with IVF technique. In our study, these two indicators were quite high values, but there is no difference between the 2 groups ($p > 0.05$). Compared with the study by Nguyen Manh Ha (2001) on 5 samples of abnormally heavy semen, there was only 1 case with significant TZI and SDI [3]. This difference is due to the high rate of combined malformations in our study, accounting for 35.33 - 38.54%.

In terms of the microscopic characteristic of sperm obtained from the testes: Out of 9 testicular tissue samples sent as superstructures, sperm was found in 02 samples. Most of the samples were abnormal as head defects, even discontinuous head membrane of the cell, abnormal shapes of the terminal pockets. In the nucleus of some cells, chromatin densities are heterogeneous, there are defect areas represented by low electron density areas. The cytoplasm is thick, the mitochondria in the tail lose the folds. These indicate that the sperm obtained

from the testes is in the process of maturation or in other words, the testicular tubes have the task of perfecting the structure and functioning in the maturation process of the sperm.

CONCLUSION

The ratio of sperm collection by using micro testes in NOA patients after the treatment of using the "Hoi xuan hoan" capsules was 46.34%, in which the sperm density, sperm survival rate, normal sperm morphology and mobile sperm in the group were treated by "Hoi xuan hoan" capsules higher than those of untreated group, especially sperm density. The "Hoi xuan hoan" capsule helps to improve the sperm production process within the testes, increasing the chances of acquiring sperm in patients with sperm production deficient.

REFERENCES

1. Trần Thị Phương Mai, Nguyễn Thị Ngọc Phương và CS. Hiếm muộn - Vô sinh và kỹ thuật hỗ trợ sinh sản. Nhà xuất bản Y học 2002.
2. Đoàn Minh Thụy. Nghiên cứu tính an toàn và hiệu quả của bài thuốc "Hồi xuân hoàn" trong điều trị bệnh nhân bị suy giảm tinh trùng. Luận án Tiến sĩ Y học. Trường Đại học Y Hà Nội 2010.
3. Nguyễn Mạnh Hà. Nghiên cứu đặc điểm hình thái vi thể tinh trùng noni. Luận văn Thạc sĩ Y học. Đại học Y Hà Nội 2001.
4. Zhou SH, Deng YF, Weng ZW, et al. Traditional Chinese medicine as a remedy for male infertility: A review. *World J Mens Health* 2019; 37(2):175-185.
5. World Health Organization. Laboratory manual for the examination and processing of human semen. Cambridge University Press, Cambridge 2010.
6. Ishikawa T. Surgical recovery of sperm in non-obstructive azoospermia. *Asian J Androl* 2012; 14(1):109-115.
7. Deruyver Y, Vanderschueren D, Van der Aa F. Outcome of microdissection compared with conventional in non-obstructive azoospermia: A systematic review. *Andrology* 2014; 2(1):20-24.
8. Wang Jinju, LIU Yongsheng, Zhang Qiuying. Clinical observation on yougui capsules combined with levocarnitine oral liquid for 96 cases of oligoasthenospermia. *Journal of Traditional Chinese Medicine* 2014; 55(17):1493.
9. Zhu Zhichao, Zhu Jianming, Shao Sihai. Clinical observation of Wuzi Yanzong Wan combined with Yougui Wan for Asthenospermia. *Journal of new Chinese Medicine* 2015; 47(12):79.
10. Prins GS, Dolgina R, Studney P, et al. Quality of cryopreserved testicular sperm in patients with obstructive and nonobstructive azoospermia. *Journal of Urology* 1999; 161(5): 1504-1508.