

Surgical therapy for early stage non small cell lung cancer: VATS versus Thoracotomy

Que Kim Do^{1}; Trung Anh Nguyen²*

Objectives: Non-Small Cell Lung Cancer (NSCLC) is the common cancer and the leading cause death of cancer. Lobectomy and lymph node dissection is optimal surgical treatment method for early stage of NSCLC. Video-assisted thoracoscopic surgery (VATS) approach is less trauma, quickly recovery, whereas those who advocate thoracotomy claim it as an ontologically superior procedure.

The aims of the study are to evaluate the role of Video-Assisted Thoracoscopic Surgery for treating the patients who have early stage of NSCLC and comparing with conventional thoracotomy.

Methods: All of patients with NSCLC in stage IA - IIB underwent lobectomy and lymph node dissection through VATS or thoracotomy are collected. Patient characteristics are compared. Operative data, complications are assessed and survived is assessed by Kaplan–Meier and Cox proportional hazards analysis. Follow-up from 14 to 66 months.

Results: From May 2008 to August 2016, 57 patients with NSCLC stage IA - IIB underwent an attempt at VATS lobectomy and 60 patients underwent thoracotomy. There are 75 males and 42 females, mean age is 56.3, range 31 - 84. Lobectomy was performed in 106 cases and bilobectomy was performed in 11 cases. The mean operating time in VATS group is 157 minutes longer than conventional thoracotomy,

which was 124 minutes. There was no statistic difference between 2 groups separated based on characteristics of patients. In 57 cases VATS, 5 cases were converted to thoracotomy. There was one death in conventional thoracotomy group. One patient had bleeding, needed to be re-operated to control bleeding in each group. Prolonged air-leak presented in 7 cases (10.7%) in thoracotomy and 2 cases (3.8%) in VATS group. Hospitalization is 18.4 days in thoracotomy group and 12.8 days in VATS group. The 5-year OS rate was 67.8% in the VATS group and 71.6% in the thoracotomy group ($p = 0.156$). The 5-year DFS rate was 59.6% in the VATS group and 65.9% in the thoracotomy group ($p = 0.065$). Survival by Cox model was no different for VATS versus thoracotomy (hazard ratio 0.82; $P = .21$)

Conclusion: Video-assisted thoracoscopic surgery is effective and safe method for surgical treatment of early stage of NSCLC. Surgery remains the primary therapy in the treatment of early-stage lung cancer. VATS was associated with less complication and shorter length of hospital stay. The 5 years survival is similar in VATS and conventional thoracotomy approach.

¹ Thong Nhat hospital, Pham Ngoc Thach

Medical University Ho Chi Minh city, Vietnam

² Thong Nhat hospital, Ho Chi Minh city, Vietnam

*Corresponding author: Do Kim Que,

Email: dokimque@gmail.com, Tel. 0913977628

Received: 27/06/2022 - Accepted: 20/07/2022

Key words: VATS, lobectomy, Non Small Cell Lung Cancer (NSCLC), early staged NSCLC

INTRODUCTION

Non-Small Cell Lung cancer (NSCLC) is the leading cause of cancer-related death worldwide. Surgical resection is the main curative treatment method for patients with early stage of NSCLC. The past decade has seen an increase in the use of VATS for early stage lung cancer, and a recent report based on data from the Society of Thoracic Surgeons database indicated that VATS is used for 32% of all lobectomies in the United States [2]. VATS lobectomy has been shown to be associated with less postoperative pain, less surgical morbidity, fewer morbidities, and shorter hospitalization [3–9]. However, there is still much to debate with the respect to the role of VATS in lobectomy for the treatment of lung cancer. Though the feasibility and the safety of VATS for the treatment of early stage lung cancer has been proven [8], there are persisting doubts regarding its oncological value; i.e., the potential compromise of oncological principles during surgery. We started performing VATS lobectomy in selected patients with stage IA- IIB non-small cell lung cancer (NSCLC) in 2008. We believed that the outcomes would not be inferior to those after open thoracotomy. The aims of this study are to compare the long-term survival, recurrence rate, and complications outcomes after VATS lobectomy versus opened thoracotomy lobectomy for clinical stage IA-IIB NSCLC.

METHODS

Patient characteristics:

This retrospective study includes 117 consecutive eligible patients treated in the

Department of Thoracic and Cardiovascular Surgery at Thong Nhat Hospital from May 2008 to August 2016. The inclusion criteria were: VATS lobectomy or opened thoracotomy lobectomy; and a definitive postoperative diagnosis of stage NSCLC according AJCC 7 classification [7]. The study included 42 females and 75 males. The medical records of each patient were reviewed and demographic and clinical data were recorded, including age, sex, pathology, clinical stage, and other clinicopathological factors. The protocol was conducted in accordance with the Declaration of Helsinki and Good Clinical Practice guidelines. This study was approved by the Ethical Committee of Thong Nhat Hospital.

Preoperative staging Preoperative investigations included thoracic and upper abdominal computed tomography (CT) to establish absence of multiple pulmonary lesions and absence of distal metastases; and to evaluate hilar and mediastinal lymph node status. Bronchoscopy, CEA, Cyfra 21-1 were performed routinely. Bone scintigraphy was performed if clinically indicated. F18-fluorodeoxyglucose positron emission tomography (FDG-PET) was performed within one month before surgery only when a preoperative histological diagnosis could not be obtained.

Surgical procedures:

All patients underwent curative surgery by VATS lobectomy or opened thoracotomy lobectomy. Patients were placed in the lateral decubitus position with single-lung ventilation. For VATS, a 10-mm, 30° scope was introduced through the 7th intercostal space in the mid-

axillary line. A 1 cm incision was made in the 8th intercostal space in the auscultatory triangle. A 5-cm access thoracotomy was usually placed in the 4th or 5th intercostal space in the anterior axillary line for upper/middle or lower lobectomy, respectively. The pulmonary vessels and bronchi were dissected as for open thoracotomy. Branches of the pulmonary artery were separated and ligated with 2 – 0 silk or stapled with a linear stapler. The endoscopic linear stapler was used to divide pulmonary veins and bronchi, and plication of the fissure. The resected tissue was placed in a plastic specimen bag for retrieval to avoid implantation of tumor cells. Lobectomy via open thoracotomy was performed using a 15 - 20 cm posterolateral incision sparing the serratus anterior muscle, through the 4th or 5th intercostal space. The vessels were individually dissected and divided using sutured ligation with 3-0 silk. Bronchial structures were separated and closed by 4-0 Vicryl running suture. Complete hilar and mediastinal lymph node dissection was usually performed during both VATS and open thoracotomy. In patients with severe preoperative morbidity or aged >80 years, only hilar dissection and mediastinal lymph node sampling were performed.

Pathologic study:

Resection was considered complete when the resection margins were free of disease. Pathological staging was performed according to the 7th International Staging System for Lung Cancer [7]. Histopathological examination Tumors were evaluated by an experienced pathologist and graded according to the 2004 World Health Organization classification for NSCLC.

Treatment and follow-up:

Outpatient follow-up was performed by

thoracic surgeons after operation 1 month and every 3 months until 12 months after surgery, then every 6 months until 5 years, and then yearly. Standard follow-up consisted of chest X-ray, laboratory testing including measurement of tumor markers, and clinical examination. Chest CT scan was performed every 6 months until 2 years, and then yearly. Further CT was only performed if there were suspicious radiological, serological, or clinical findings. Adjuvant chemotherapy was administered to patients with adenocarcinoma if pathologic stage II or more with Paclitaxel or Gemcitabine plus Carboplatin regimen for 4 cycles. The overall survival (OS) and disease-free survival (DFS) was estimated from the date of surgical resection until death of any cause or the date of last follow-up.

Statistical analysis

Clinicopathological factors were compared between groups using the two-tailed Pearson's chi-square test. Survival probabilities were estimated using the Kaplan– Meier method. The significance of differences in disease-free survival (DFS) and overall survival between groups were tested using the log-rank test.

RESULTS

From May 2008 to August 2016, 117 patients with clinically staged IA-IIB non-small cell lung cancer underwent surgical resection. In which, 60 underwent thoracotomy and 57 underwent attempted VATS lobectomy, of whom 5 required conversions to thoracotomy. There were no intraoperative deaths. Median follow-up was 44 months in both groups. Patient characteristics and perioperative findings are shown in Tables 1 respectively.

Table 1. Patient characteristics

	No of patients (n=117, 100%)	opened lobectomy	VATS lobectomy	p value
Age, y (mean)	56.3 (41-84)	56.6 (41-84)	56.1 (41-81)	0.61
< 70	85 (72.6)	42 (70)	43 (75.4)	
> 70	32 (37.4)	18 (30)	14 (24.6)	
Gender				
male	75 (64.1)	40 (66.7)	35 (61.4)	0.52
female	42 (35.9)	20 (33.3)	22 (38.6)	
Tumor size				
< 2 cm	7 (6.0)	2 (3.3)	5 (8.8)	0.48
2-3 cm	46 (39.3)	23 (38.3)	23 (40.3)	
3-5 cm	52 (27.4)	28 (46.7)	24 (42.1)	
> 5 cm	12 (10.3)	7 (11.7)	5 (8.8)	
c-stage				
IA	13 (11.1)	6 (10.0)	7 (12.3)	0.46
IB	24 (20.5)	12 (20.0)	12 (21.1)	
IIA	70 (59.8)	36 (60.0)	34 (59.6)	
IIB	10 (8.6)	6 (10.0)	4 (7.0)	
p-stage				
IA	10 (8.6)	5 (8.3)	5 (8.8)	0.29
IB	22 (36.7)	10 (16.7)	12 (21.1)	
IIA	64 (54.7)	33 (55.0)	31 (54.3)	
IIB	9 (7.7)	4 (6.7)	5 (8.8)	
IIIA	12 (10.3)	8 (13.3)	4 (7.0)	
Histology				
Adenocarcinoma	78 (66.7)	40 (66.7)	38 (66.7)	0.51
Squamous cell carcinoma	34 (29.0)	18 (30.0)	16 (28.1)	
Others	5 (4.3)	2 (3.3)	3 (5.2)	
cN				
N0	65 (55.6)	32 (53.3)	33 (57.9)	0.28
N1	52 (44.4)	28 (46.7)	24 (42.1)	
N2	0	0	0	
pN				
N0	41 (35.0)	18 (30.0)	23 (40.3)	0.21
N1	64 (54.7)	34 (56.7)	30 (52.7)	
N2	12 (10.3)	8 (13.3)	4 (7.0)	
Operation time (min.)	143.6	124.1	157.2	0.08
Bleeding (ml)	160.6	182.4	148.2	
Air leakage				
>24h	12 (10.3)	7 (11.7)	5 (8.8)	0.12
>5 days	9 (7.7)	7 (11.7)	2 (3.5)	
length of hospitalization (day)	12.2	14.4	8.5	0.04

Disease-free and overall survival

The median follow-up time was 42.3 months. The 5-year OS rate was 67.8% in the VATS group and 71.6% in the thoracotomy group ($p = 0.156$, Figure 1a). The 5-year DFS rate was 59.6% in the VATS group and 65.9% in the thoracotomy group ($p = 0.065$, Figure 1b).

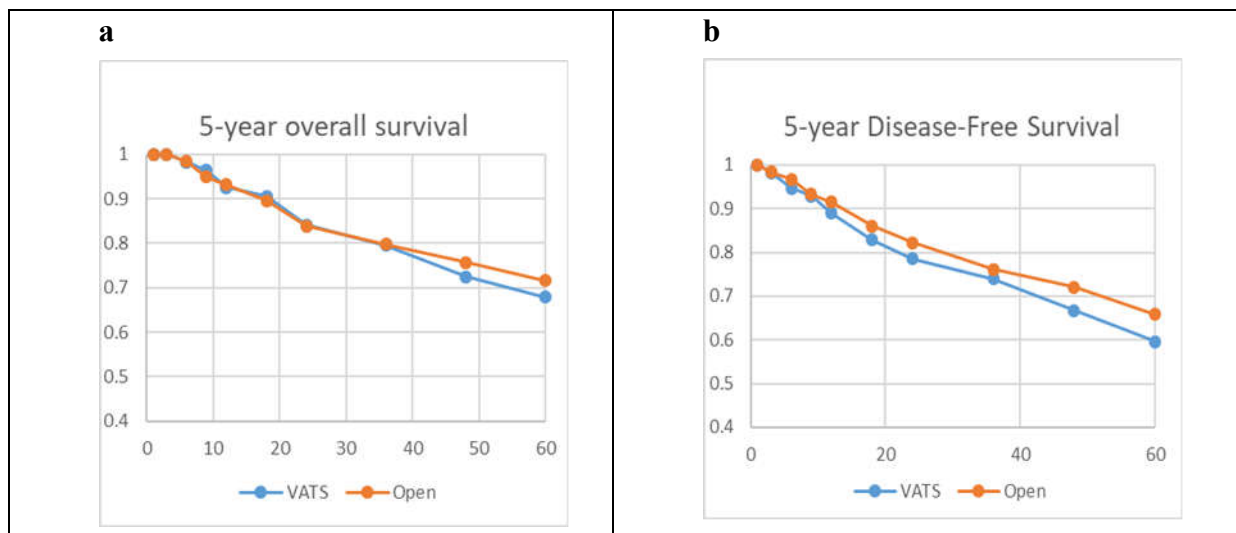


Figure 1. Five-year overall survival(OS) (a) and disease-free survival (DFS) (b). The 5-year OS rate was 67.8 % in the VATS group and 71.6% in the thoracotomy group ($p = 0.156$) and the 5-year DFS rate was 59.6% in the VATS group and 65.8% in the thoracotomy group ($p = 0.065$).

Among patients with stage IA-IB NSCLC, the 5-year OS rate was 80.4% in the VATS group and 86.5% in the thoracotomy group ($p = 0.114$, Figure 2a). In patients with stage IIA-IIB NSCLC, the 5-year OS rate was 61.0% in the VATS group and 66.9% in the thoracotomy group ($p = 0.089$, Figure 2b).

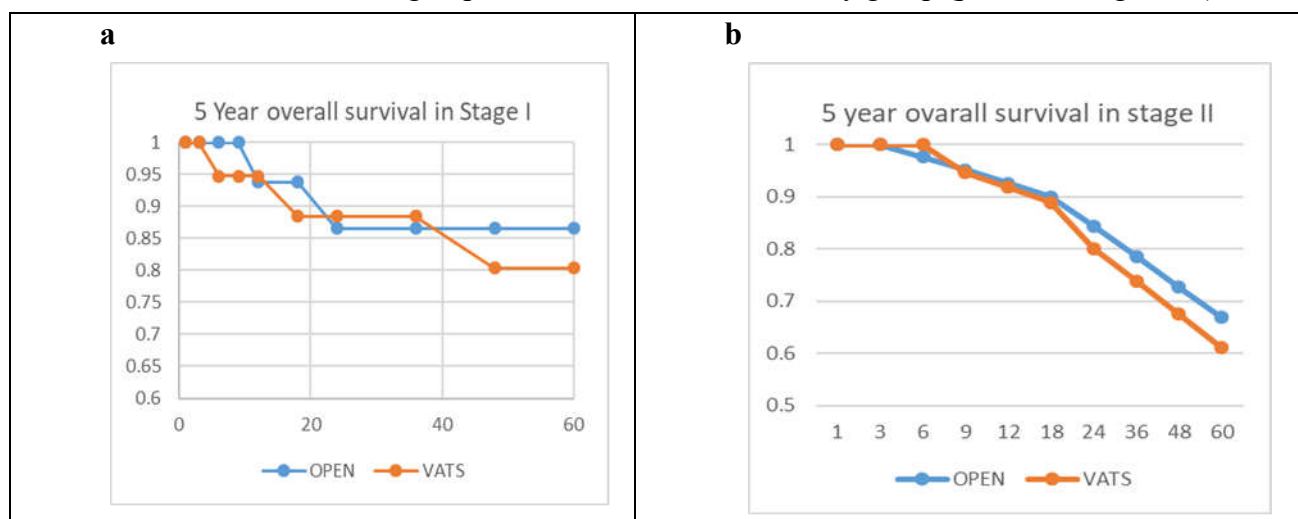


Figure 2. Five-year overall survival(OS) for patients with clinical stage I NSCLC (a) and patients with stage II NSCLC (b). The 5-year OS rate was 80.4 % in the VATS group and 86.5% in the thoracotomy group ($p=0.114$) for patients with stage I NSCLC and the 5-year OS rate was 61.0% in the VATS group and 66.9% in the thoracotomy group ($p = 0.098$).

DISCUSSION

In this study, we found that VATS lobectomy could perform safely for early stage NSCLC, conversion thoracotomy rate was 8.8%, most of case due to tumors or lymph node invade to vessels. Prolonged air leak was 3.5% in VATS group compare to 11.7% in opened group. Whitson et al.[7] reported prolonged air leak of more than 7 days (56%).

Major benefits of VATS relate to reduced pain following surgery. Pain was demonstrated to occur in up to 50–70% of patients at two months or more after thoracotomy procedures using a retractor, and over 40% of patients may still have some degree of pain at one year after surgery, with 5% of patients experiencing significant levels of pain. Pain can cause a number of peri- and postoperative complications both immediately and long after the surgery [4].

In this study, the operating time was longer in VATS group versus opened lobectomy. In a study by Sakuraba et al. [4], statistically significant differences were demonstrated in 752 patients who underwent either video-assisted thoracoscopic or open lobectomy: shorter median operative time (video-assisted thoracoscopy 117.5 minutes versus open 171.5 minutes), lower chest tubes drainage (987mL in video-assisted thoracoscopy versus 1504mL in open lobectomy), and shorter length of stay (4.5 days versus 7 days). A statistically significant difference was also found in perioperative blood loss to the advantage of VATS.

The long-term outcomes of VATS lobectomy group for early stage NSCLC is similar opened lobectomy. In this study, 5-year OS rate was 67.8% in the VATS group and 71.6% in the thoracotomy group ($p = 0.156$). The

5-year DFS rate was 59.6% in the VATS group and 65.9% in the thoracotomy group ($p = 0.065$). Yan et al. [8] performed a similar systematic review and found that the 5-year survival rate was significantly higher in patients who underwent VATS lobectomy than those who underwent open thoracotomy for early-stage NSCLC (VATS relative risk, 0.72; $p = 0.04$). The significantly better OS in the VATS group reflects the inaccurate preoperative diagnosis of clinical stage IA NSCLC in some patients. Preoperative staging was based on the findings of imaging examinations such as CT and F18-fluorodeoxyglucose positron emission tomography. The rate of accurate diagnosis of clinical stage IA NSCLC was 71.9% in the VATS group and 56.5% in the thoracotomy group ($p = 0.2611$).

Taking into the consideration that selection bias influences the rate of accurate diagnosis of clinical stage I and II NSCLC. For example, VATS lobectomy is considered preferable in female patients with small adenocarcinomas, whereas male patients with squamous cell carcinoma are less likely to be selected for VATS lobectomy because they may have emphysematous lungs and non-specific lymph node enlargement due to heavy smoking or their working history, which may increase the difficulty of surgery.

Merritt et al. [3] reported that lymph node dissection may be inadequate during VATS lobectomy. Boffa et al. [1] also showed the incompleteness of the peri-bronchial and hilar node evaluation in the VATS group. In this study, there was 10.3% upstaging from N0 or N1 to N2. These results suggest that VATS lobectomy is a feasible treatment for pathological stage IA

NSCLC and indicate that differences in nodal upstaging result from patient selection. However, this study found that local control was better in the VATS group, and the prognosis of patients with clinical stage I and stage II NSCLC was not significantly different between the VATS and thoracotomy groups. These results suggest that VATS lobectomy is a feasible treatment for clinical stage I or II NSCLC. The long-term outcomes after VATS lobectomy still require further evaluation. The present study is limited by its retrospective nature, and a larger prospective randomized study is required to reach definitive conclusions regarding the efficacy of VATS lobectomy for the treatment of NSCLC.

Conclusions

Video-assisted thoracoscopic surgery is an effective and safe method for surgical treatment of early stage NSCLC. The 5-year DFS and OS were similar after VATS compared with thoracotomy in clinical stage I and II NSCLC. Length of hospitalization stay was shorter in group VATS.

REFERENCES

1. Boffa DJ, Kosinski AS, Paul S, Mitchell JD, Onaitis M: Lymph node evaluation by open or video-assisted approaches in 11,500 anatomic lung cancer resections. *Ann Thorac Surg* 2012; 94:347–53.

2. McKenna RJ Jr: Lobectomy by video-assisted thoracic surgery with mediastinal node sampling for lung cancer. *J Thorac Cardiovasc Surg* 1994; 107:879–882.

3. Merritt RE, Hoang CD, Shrager JB: Lymph node evaluation achieved by open lobectomy compared with thoracoscopic lobectomy for N0 lung cancer. *Ann Thorac Surg* 2013; 96:1171–1177.

4. Sakuraba M, Miyamoto MH, Oh S et al., “Video-assisted thoracoscopic lobectomy vs. conventional lobectomy via open thoracotomy in patients with clinical stage IA non-small cell lung carcinoma,” *Interactive Cardiovascular and Thoracic Surgery*, 2007; 6 (5):614–617.

5. Shigemura N, Akashi A, Nakagiri T, Ohta M, Matsuda H: Complete versus assisted thoracoscopic approach: A prospective randomized trial comparing a variety of video-assisted thoracoscopic lobectomy techniques. *Surg Endosc* 2004; 18:1492–1497.

6. Whitson BA, Groth SS, Duval SJ, Swanson SJ, Maddaus MA, “Surgery for early-stage non-small cell lungcancer: a systematic review of the video-assisted thoracoscopic surgery versus thoracotomy approaches to lobectomy,” *Annals of Thoracic Surgery*, 2008; 86 (6): 2008–2018.

7. Winton T, Livingston R, Johnson D, Rigas J, Johnston M, Butts C, Cormier Y, Goss G, Inculet R, Vallieres E, Fry W, Bethune D, Ayoub J, Ding K, Seymour L, Graham B, Tsao MS, Gandara D, Kesler K, Demmy T, Shepherd FA, National Cancer Institute of Canada Clinical Trials Group; National Cancer Institute of the United States Intergroup JBR.10 Trial Investigators: Vinorelbine plus cisplatin vs. observation in resected non-small cell lung cancer. *New Eng J Med* 2005; 352:2589–2597.

8. Yan TD, Black D, Bannon PG, McCaughan BC: Systematic review and meta-analysis of randomized and nonrandomized trials on safety and efficacy of video-assisted thoracic surgery lobectomy for early-stage non-small cell lung cancer. *J Clin Oncol* 2009; 27:2553–2562